

# Case Series: Treatment of Complex Post-Operative Vascular Wounds with a Novel Transforming Powder Dressing (TPD)

Johnathan A. Allen, PA-C; Xiomara Benavide-Lopez, MD; Bessie M. Roca Loor, MD; Dian G. Nesbeth, NP; Rebecca K. Barksdale, RN; Nicholas Quartararo; Rajiv K. Chander, MD  
 Division of Vascular Surgery, James J. Peters Veterans Affairs Medical Center, Bronx, New York 10468

## INTRODUCTION

Vascular ulcers occur in an estimated 1 to 3 percent of adults worldwide and remain a public health issue with significant economic and psychosocial impacts.

Wound management of vascular ulcers requires frequent dressing changes and drain valuable material and labor resources.

This case series aimed to evaluate the safety and efficacy of utilizing a novel transforming powder dressing (TPD\*) with extended wear time as an alternative treatment modality in three patients with complex vascular wounds of varying etiologies.

## METHODOLOGY

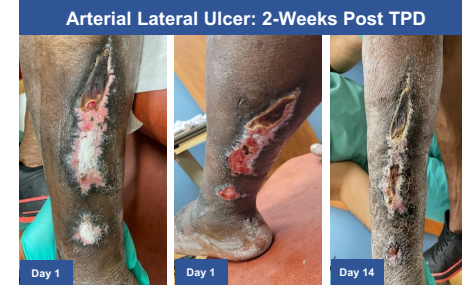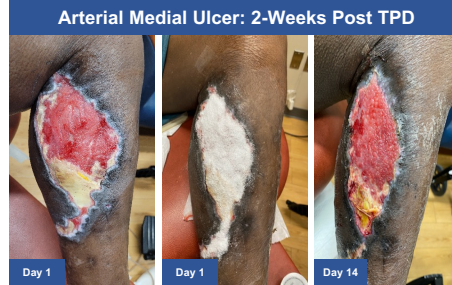
We performed an observational case series assessment on complex wounds of differing etiologies resultant of sequela related to severe vascular pathology. Each patient was observed to have significant co-morbidities complications with history of poor wound healing and one or more wounds refractory to standard of care (SOC) treatment and required consideration for alternate treatment to facilitate wound healing. Three patients were treated with TPD. Patient demographics, past medical and surgical history, and anatomical pathology were described. Evaluation of wound closure progress was followed with the participation of multi-specialty teams.

## RESULTS

### #1. ARTERIAL INFECTED / NECROTIC ULCER

- 71 y/o male, PVD with claudication, CLI
- Left fem-pop bypass in-situ c/b infection. Subsequent native artery revascularization, bypass coil embolization/ligation, refractory ulcer post distal infective / necrotic tissue evacuation

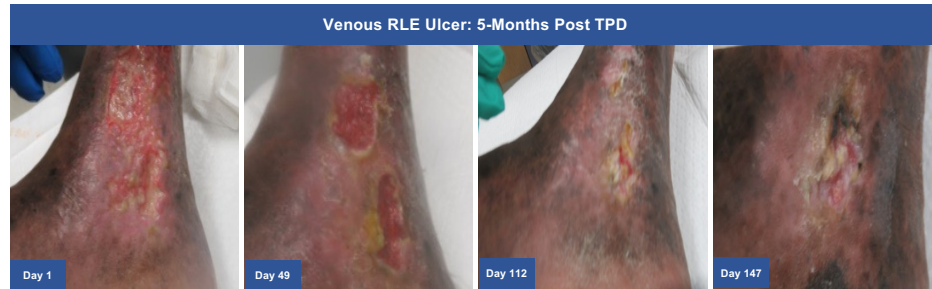**Outcome:** TPD used at home with good healing. Dressing changes reduced from once every 2 days (NPWT) to once a week (TPD).



### #2. REFRACTORY VENOUS ULCER

- 73 y/o male, refractory VLU
- Bilateral GSV ablations

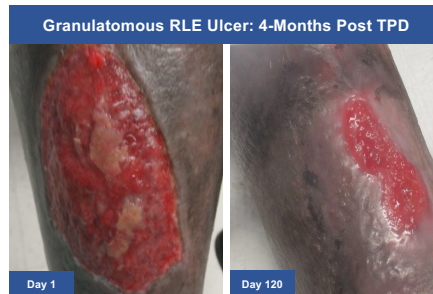**Outcome:** LLE ulcer healed and RLE ulcer was significantly reduced with TPD. Dressing changes reduced from once every other day (various antimicrobial dressings) to once a week (TPD).



### #3. REFRACTORY GRANULOMATOUS ULCER

- 74 y/o male, PVD progressed to rest pain, CLI
- Right fem-AT bypass with PTFE. Disease progression at distal anastomosis with jump bypass from PTFE to distal AT using basilic vein

**Outcome:** Significant wound area reduction of chronic granulomatous wound with TPD. Dressing changes reduced from thrice (various antimicrobial dressings) to once per week (TPD).



## CONCLUSION

All patients experienced accelerated healing and wound area reduction with TPD despite significant co-morbidities, vascular complications, and poor history of wound healing. Based on these results, we conclude that TPD is appropriate for use in complex vascular wounds with varying etiologies: active infection, venous stasis, and chronic granuloma wounds. TPD has the benefit of promoting wound healing while being a less expensive alternative to other modalities that require more frequent dressing changes and is easy to use in both clinic and home settings.

\*Altrazeal® Transforming Powder Dressing, USA. For application instructions and risks of this device please refer to Altrazeal Instructions for Use. Acknowledgements: This poster was created in collaboration with ULURU Inc. All clinical cases and analyses were performed independently by the authors and no compensation was paid.