

# Novel Transforming Methacrylate Dressing Use in Asian Pediatric Patients: Our Initial Experience

C. H. Pek<sup>1</sup>, G. J. S. Lim<sup>2</sup>, T. Y. Kong<sup>2</sup>, Y. C. Por<sup>2</sup>

<sup>1</sup>Department of General Surgery, Plastic, Reconstructive and Aesthetic Surgery Section, Tan Tock Seng Hospital, 11 Jalan Tan Tock Seng, Singapore 308433, <sup>2</sup>Department of Plastic, Reconstructive and Aesthetic Surgery, KK Women's and Children's Hospital, 100 Bukit Timah Road, Singapore 229899

## ABSTRACT

Altrazeal<sup>®</sup>, or transforming methacrylate dressing (TMD), is a unique dressing consisting of a powder-based dressing that transforms to a flexible dressing on contact with exudate or sterile solution. Unlike conventional dressings, it possesses many unique physicochemical properties which allow it to overcome the common barriers to wound healing. We report the successful use of this TMD in various clinical scenarios and discuss its potential advantages.

**Key words:** Altrazeal, transforming methacrylate dressing, wound dressing, wound healing

## INTRODUCTION

A plethora of wound dressings is available on the market which can be used in different wound conditions and clinical scenarios. The ideal wound dressing should aim to protect the wounded area from further loss of tissue and external contamination while providing an optimum environment for wound healing.<sup>[1]</sup> In addition, the ideal wound dressing should also be comfortable and affordable for the patient, preferably with less frequent dressing changes required. Traditional dressings available often fall short in one aspect or another, as we continue to seek the ideal wound dressing.

As a compound, the use of poly(2-hydroxyethyl methacrylate) (pHEMA) was first proposed more than three decades ago. Migliaresi *et al.*<sup>[2]</sup> described a compound consisting of pHEMA with a polybutadiene layer which was thermally grafted on; this was suggested to have desirable properties as potential burn covering. Further, experiments conducted on pHEMA focused on antibiotic additives, which showed decreased bacterial counts and better pain scores in patients.<sup>[3]</sup> Since then, there is a growing interest in the applications of

nanotechnology to the field of wound dressings. More recent research efforts have renewed interest in this compound, with the latest product consisting of pHEMA and poly(2-hydroxypropylmethacrylate). This powder-based dressing, also known as Altrazeal<sup>®</sup> (Uluru Inc., Addison, TX), transforms to a flexible dressing on contact with exudate or any sterile solution, and possesses many unique physicochemical properties.

We discuss a series of pediatric patients successfully treated with this transforming methacrylate dressing (TMD) in an Asian tertiary pediatric hospital.

## CASE REPORT

### Patient 1

A 3-year, 10-month-old boy presented emergently after hot water scalded his left upper limb and left thigh region, total body surface area (TBSA) estimated to be about 10%. Examination revealed blistered skin and superficial partial-thickness burns of the left hand, forearm, and thigh [Figure 1]. The patient's parents declined Biobrane (UDL Laboratories, Rockford, IL) dressing application due to personal reasons; hence, all the

### Address for correspondence:

C. H. Pek, Department of General Surgery, Plastic, Reconstructive and Aesthetic Surgery Section, Tan Tock Seng Hospital, 11 Jalan Tan Tock Seng, Singapore 308433. E-mail: pekch@rocketmail.com

© 2018 The Author(s). This open access article is distributed under a Creative Commons Attribution (CC-BY) 4.0 license.

burn wounds were managed conservatively with silver-based foam dressing. After a week of dressing, the burns over the left thigh converted to deep dermal burns [Figure 1], and the patient also started to have fever. This measured an area of approximately 12 by 8 cm. We counseled the patients' parents for surgical debridement, with a possibility of skin grafting. After superficial debridement, the burn wounds were assessed to be still amenable for a trial of dressing therapy. Hence, the burn wounds were thoroughly cleansed and the TMD was started for the patient's left thigh burns. No skin graft was required. Subsequent dressings were changed once weekly and after 2 weeks most of the thigh burns had epithelized [Figure 1]. The patient continued on the TMD and achieved full epithelization of his thigh burns another 2 weeks later. The patient was reviewed at 6 weeks post-epithelization, which revealed a soft and pliable scar over the left thigh [Figure 1].

### Patient 2

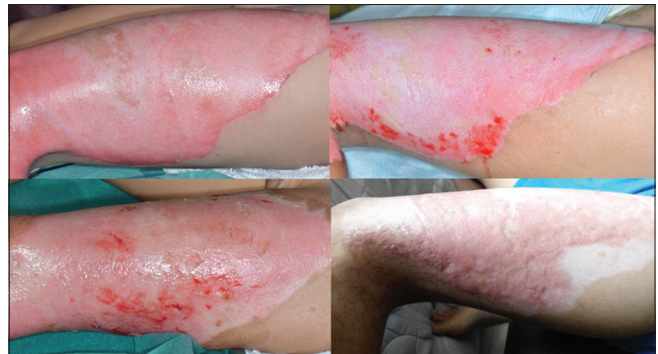
A 10-year-old boy presented to us after he had scalded his right heel during a camping accident. He had accidentally upended a small pot of hot oil over his right heel and sought treatment at the emergency department immediately after. He was consulted in the plastic surgery clinic the very next day, and clinical examination revealed an 8 by 4 cm area of partial-thickness burn over the tendo-Achilles region of the right heel [Figure 2]. The initial dressing was done with silver-based foam dressing. 2 weeks later, his burns progressed to an area of deeper dermal burn measuring 2 by 5 cm. As the patient refused surgical intervention at that time, a decision was made to start TMD at an outpatient setting [Figure 3]. After weekly dressing change with TMD, the patient's wound successfully healed after 3 weeks of dressing. The healed scar was soft and supple and did not limit movement of the ankle joint [Figure 2].

### Patient 3

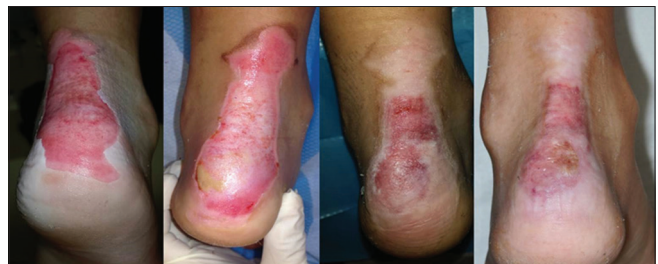A 2-year-old girl presented to us with a burn wound on her left ankle after she was accidentally scalded by hot water. She presented to us 4 days after her burn injury, and her family physician was treating her burn wound with simple gauze dressing before presentation. In addition, she had been having fever and increasing pain over the left ankle for the past 2 days. On examination, she had deep dermal burns on her medial and dorsum of her left ankle amounting to approximately 1% TBSA. The burned area was sloughy and foul smelling. Versajet (Smith and Nephew, Hull, UK) debridement and immediate split-thickness skin graft were performed for the patient for the patient. The split-thickness skin graft was harvested at 8/1000<sup>th</sup> inch thickness from the ipsilateral thigh using an electrical dermatome [Figure 4]. TMD was applied to the skin graft donor site, which was hydrated with 10 ml of 0.5% bupivacaine instead of saline for additional pain relief. Simple gauze dressing was done as a secondary dressing. Her recovery was uneventful, and both her skin graft and donor site healed after 2 weeks [Figure 4].

## DISCUSSION

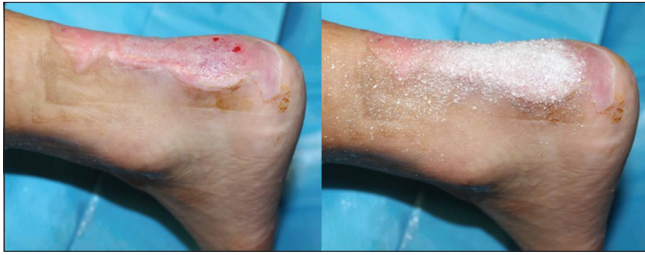Since the first description of methacrylate as a form of dressing by Migliaresi, has allowed the formulation of TMD which may be the ideal wound dressing in certain clinical scenarios.<sup>[2]</sup> This dressing is a synthetic hydrogel-based powder consisting of lyophilized particles which transforms into a wound conforming, flexible dressing after coming into contact with wound



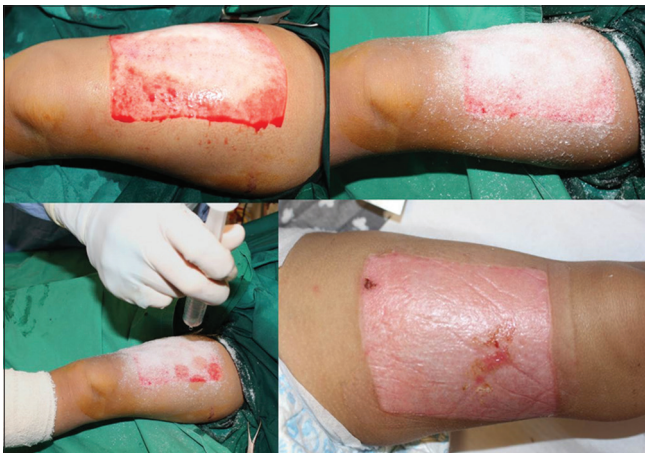**Figure 1:** Management of the left thigh burns with transforming methacrylate dressing (TMD) Top left: A 3-year, 10-month-old boy with the left thigh partial-thickness burns at presentation. Top right: Conversion of the left thigh burns, with patches of both mid and deeper dermal burns after 1 week of silver-based foam dressing. Bottom left: Appearance of epithelization of the left thigh burns, after treatment with TMD or Altrazeal® for 2 weeks. The patient was treated with TMD for 2 weeks, with wound inspection and dressing change done every 7<sup>th</sup> day. Bottom right: Healed wounds with soft and pliable scars of the left thigh. The scars were slightly hypertrophic and hyperpigmented at 6 weeks



**Figure 2:** Management of the right heel burns with transforming methacrylate dressing (TMD). From leftmost: A 10-year-old boy with the right heel burns from oil scalding injury at presentation. Second from left: Further conversion of the right heel burns with a 2 by 5 cm area of deep dermal burns surrounded by partial-thickness burns sited the Achilles tendon. Second from right: Appearance of the right heel burns after 2 weeks of TMD. Areas of partial-thickness burns have epithelized well, with central deep dermal component still healing. Rightmost: Appearance of the right heel burns that had fully epithelized. There is a small scab which corresponds to an accidental scratch by the patient 1 day before the time of the photograph



**Figure 3:** Application of transforming methacrylate dressing (TMD) over the right heel burns. A uniform layer of powder (TMD) is applied to the wound (Right). The wound is subsequently hydrated with sterile solution or exudate to allow it to transform into the conforming dressing. The second layer of powder is applied on top in the same fashion if required. Secondary dressing such as non-adherent foam dressing or simple gauze dressing is applied after TMD has adhered



**Figure 4:** Management of the left thigh split-thickness skin graft (STSG) donor site with transforming methacrylate dressing (TMD). Top left: Split-thickness skin graft donor site, just after harvest with an electrical dermatome at 8/1000<sup>th</sup> inch thickness. Top right: Application of TMD as previously described. Bottom left: Hydration of TMD with 0.5% bupivacaine in saline solution, instead of normal saline. This allows for added analgesia to the donor site. Bottom right: Appearance of epithelized skin graft donor site after 2 weeks

exudate, saline, or other sterile solutions. In addition, it has capillary channels which maintain the optimum environment for moist wound healing.<sup>[3-5]</sup> This dressing also seals the wound edges and is impermeable to bacteria, thus it serves to reduce the risk of further bacterial contamination.<sup>[4]</sup>

The TMD easily conforms to any irregular wound surface and eliminates any dead space between the wound-dressing interfaces.<sup>[4]</sup> In addition, the aggregated dressing contains approximately 68% water, which is similar to the water content of the skin (72–74%), increasing its biocompatibility. Furthermore, a recent study by Forstner *et al.*<sup>[3]</sup> has shown that TMD can be loaded with various antiseptics, serving as a drug delivery system to the applied wound.

In our clinical practice, we have found that the TMD conforms easily, regardless of the complexity of the wound surface. In addition, the increased patient comfort after dressing application corroborates the findings of earlier related studies.<sup>[4,5]</sup> Due to its unique capillary channel design for moisture control, it allows for optimal oxygen transport and at the same time provides optimal exudate control. In turn, this reduces the need for secondary dressing and effectively decreases the frequency of dressing change as well. We believe that the TMD creates the optimal conditions for moist wound healing,<sup>[6]</sup> and we believe this accelerates the rate of epithelization of the wounds. These properties mentioned make TMD a useful dressing option in pediatric patients.

In patient 1's situation, we had successfully avoided the need for skin graft and an additional donor site scar with the use of TMD. We believe that the TMD provided the optimal conditions to allow for moist wound healing and rapid epithelization. For patient 2, in addition to avoiding the need for skin grafting, the TMD dressing also showed its superiority as a versatile adherent dressing in an area that was difficult to dress. Once the TMD formed an adherent scab over the wound, we were able to expose the area much earlier than we would have with traditional dressings. Finally, for patient 3, we used sterile 0.5% bupivacaine solution to hydrate the TMD instead of sterile saline used in the first two patients. We postulate that by doing so, the TMD would act as a drug delivery vehicle, similar to the mechanism described for antibiotics by Forstner *et al.*<sup>[3]</sup> We would not have used the TMD directly on the burn wound for patient 3 in view of the possibility of infection.

The TMD provides a useful tool in the plastic surgeon's armamentarium for varying clinical scenarios, and it is comfortable for the patient. In addition, it has the advantage of being a drug delivery vehicle directly to the wound has shown its benefits especially in decreasing the risk of infections. Our overall clinical experience is that the TMD dressing is just as comparable and efficacious as the standard dressings used in the right clinical setting. In addition, TMD is able to cover a large surface area comfortably, up to 15 by 15 cm surface area, with one packet. Over the treatment course of 2–3 weeks, the cost of this dressing material is affordable and economical. Specific to pediatric burns, the indication for TMD use would be limited to non-infected burns that are mid to deep partial-thickness burns and do not require immediate excision and skin grafting. This, in turn, potentially saves the patient a donor site scar as a result of skin graft harvest.

Traditional dressings are often easily dislodged by active infants and children or do not conform well especially over mobile joints. In an attempt to prevent dislodgement or to conform the primary dressing well, tight and often bulky secondary dressings are required which may cause discomfort



to the patient. The TMD would be useful for pediatric patients because it is comfortable yet conforms well to any wound surface, providing a semi-occlusive environment for moist wound healing and prevention of wound infections. A light secondary gauze dressing would suffice in most cases, and the TMD allows for early exposure of the wound, with the adherent scab falling off effortlessly after wound epithelization beneath the scab.

As no dressing is perfect, TMD does have its disadvantages. We found that application of the TMD over convex surfaces can prove challenging as the particulate matter tends to get caught in the updraft of the operating room ventilators. Special effort has to be made to reposition the convex surface of a limb, for instance, to allow even distribution of the TMD over the three-dimensional wound. A lot of the TMD gets wasted during this application process as it falls outside the wound. To ameliorate this problem, we have resorted to opening just a slit in the foil packaging and sprinkling the TMD onto the wound in small quantities at a time. We have also experienced adhesion of the secondary dressing to the TMD resulting in pain on removal of the secondary dressing. This can be alleviated by soaking the secondary dressing in saline for 5 min before removal.

Our study is limited by the lack of long-term follow-up and the eventual appearance of the scar. Further studies and additional patients are required for a better understanding of the benefits and limitations of the TMD.

## CONCLUSION

The unique properties of TMD allow it to be a useful wound dressing option in various wounds. Its notable advantages compared to conventional dressings are (1) relative ease of

application, (2) increased comfort for the patient, and (3) the ability to conform to any wound surface. Our overall clinical experience is that the TMD dressing is just as comparable and efficacious as the standard dressings used in the right clinical setting.

## REFERENCES

1. Değim, Z. Use of microparticulate systems to accelerate skin wound healing. *J Drug Target* 2008;16:437-48.
2. Migliaresi C, Carfagna C, Nicolais L. Laminates of poly(2-hydroxyethyl methacrylate) and polybutadiene as potential burn covering. *Biomaterials* 1980;1:205-8.
3. Forstner C, Leitgeb J, Schuster R, Dosch V, Kramer A, Cutting KF, *et al.* Bacterial growth kinetics under a novel flexible methacrylate dressing serving as a drug delivery vehicle for antiseptics. *Int J Mol Sci* 2013;14:10582-90.
4. Fitzgerald RH, Bharara M, Mills JL, Armstrong DG. Use of a nanoflex powder dressing for wound management following debridement for necrotising fasciitis in the diabetic foot. *Int Wound J* 2009;6:133-9.
5. Assadian O, Arnoldo B, Purdue G, Burris A, Skrinjar E, Duschek N, *et al.* A prospective, randomised study of a novel transforming methacrylate dressing compared with a silver-containing sodium carboxymethylcellulose dressing on partial-thickness skin graft donor sites in burn patients. *Int Wound J* 2015;12:351-6.
6. Leaper DJ, Schultz G, Carville K, Fletcher J, Swanson T, Drake R, *et al.* Extending the TIME concept: What have we learned in the past 10 years?(\*). *Int Wound J* 2012;9 Suppl 2:1-9.

**How to cite this article:** Pek CH, Lim GJS, Kong TY, Por YC. Novel Transforming Methacrylate Dressing Use in Asian Pediatric Patients: Our Initial Experience. *Clinic Res Dermatol* 2018;1(1):1-4.