

# OPTIMIZING CARE OF PERI-STOMAL SKIN COMPLICATIONS WITH A NOVEL TRANSFORMING POWDER

Janie Hollenbach DNP, RN, WCC, OMS, DWC, CHRNP and Susan Rolniak St. John<sup>b</sup> MSN, APRN-NC

<sup>a</sup>Wound and Ostomy Nurse, Department of Colon and Rectal Surgery, Allegheny Health Network, Pittsburgh, PA | <sup>b</sup>Clinical Consultant, ULURU Inc.

Symposium on Advanced Wound Care (SAWC) Spring Meeting, April 2022

## BACKGROUND | RATIONALE

Patients with Crohn's Disease and stomas frequently develop peri-stomal skin complications such as wounds and Pyoderma Gangrenosum (PG) that are challenging to manage. These patients often experience excruciating pain in the wounds. Enterostomal leakages also exacerbate existing skin damage making it difficult to secure stomal appliances.

The resulting increase in the frequency of appliance and wound dressing changes aggravates pain and frustration, decreases quality of life, and increases overall costs of care. Traditional dressings used to manage such wounds often require daily dressing changes multiplying the time, materials and labor needed to provide adequate care.

The purpose of this poster is to introduce ostomy and wound care clinicians to a new technique for managing peristomal skin and wound complications using Altrazeal® Transforming Powder Dressing (TPD).

A methacrylate-based novel wound modality, TPD is available in the form of sterile white granules. Upon hydration, TPD granules aggregate over the wound bed to form a moist, oxygen permeable barrier that conforms to and seals the wound surface while allowing fluid and gaseous exchange and preventing bacterial penetration. TPD may be left on the wound for up to 4 weeks.

## OBJECTIVE

The objective was to test the feasibility of TPD in simplifying care of complicated peri-stomal wounds.

## METHOD

TPD's performance was tested in a challenging case involving a patient with significant systemic and peristomal wound complications including:

- **Crohn's disease**
- **Pyoderma Gangrenosum (PG)**
- **Moisture associated dermatitis (MAD)**
- **Chemical (irritant) dermatitis**

## THE CHALLENGE: A CASE STUDY<sup>1</sup>

Female, 60 years old with:

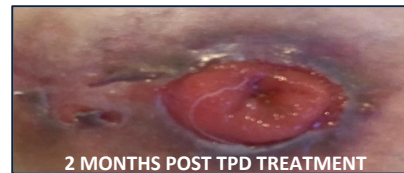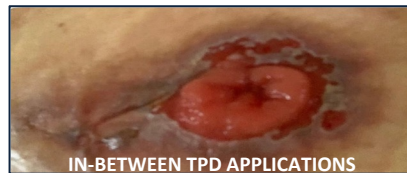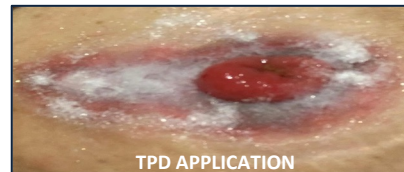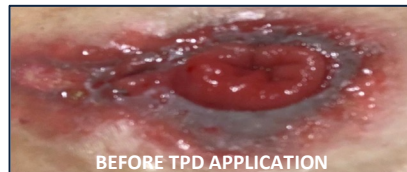- **Crohn's Disease for 26 years with 27 hospitalizations**
- **Ileum resection, colostomy, loop colostomy revision secondary to hernia complication**
- Diagnosed with **peri-stomal PG 3 years ago**
- **18%+ unintentional recent weight loss**
- **Excruciating pain (10/10 based on VAS score)** secondary to PG and irritant dermatitis requiring
  - Narcotics
  - Hospital admissions for pain management
  - Frequent appliance changes due to severe burning pain around the stoma
- **Poorly fitting ostomy appliance and irritant dermatitis** from leaking stool

**Failed Treatments:** Tested **several devices and dressings**. In addition, injectable and topical steroids were tried without improvement. **Opioids** were taken every six hours to control pain.

**Onerous Care Regime:** Daily or **twice daily appliance changes** performed by the patient with **homecare nurse visits every other day** for ostomy evaluation and wound care.

## TREATMENT WITH TPD

TPD was used as a **"last resort"** after consultation with the patient's gastroenterologist to manage moisture and exudate of peristomal wounds, protect the skin with MAD and irritant dermatitis, and cover PG wounds. TPD was applied after wound cleansing and covered with the appliance. The appliance remained in place over TPD without further leakage of stool.



## REFERENCES | ACKNOWLEDGEMENTS

1. Real life case study, self-reported, photographed, and provided to authors with patient permission and encouragement to share her success story with other patients with similar issues.
2. Manufactured in USA by ULURU Inc. Please see Altrazeal Instructions for Use for a complete listing of indications for use, warnings and precautions.
3. This work was supported by ULURU Inc.

## OUTCOMES | CONCLUSION

**All peri-stomal skin complications, pain, and wounds were resolved** while using TPD. Within 1 week, pain reduced from severe to minimal and wound quality improved markedly. Skin complications were resolved within days and the appliance was worn comfortably for 4 days continuously, without pain or leakage. All oral pain medications were discontinued.

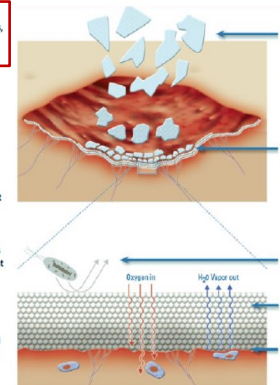
- **Pain scores dropped from 10/10 to 0/10** within minutes of TPD application
- **All wounds healed within two months**
- **Significantly improved patient's quality of life**
- TPD application also resulted in several **cost savings:**
  - **Reduced home nursing visits**
  - **Eliminated pain medications**
  - **Reduced appliance changes, supplies and labor costs**
  - **Avoided readmission for permanent ileostomy**

**Conclusion:** Challenging ostomy complications can be successfully managed and resolved. Involving specialists and adoption of new technologies like TPD are key to delivering successful interventions and outcomes.

## ABOUT TPD<sup>2</sup>

### HOW IT HELPS:

- **Wear time up to 30 days:** reduces dressing changes, wound disturbance and exposure to infections
- **Non-occlusive barrier:** blocks entry of external bacteria but allows moisture and oxygen transportation
- **Optimum moisture balance:** absorbs moisture up to 68% (similar to skin tissue) but permits excess moisture to flow out
- **Translucent cover:** allows wound inspection without dressing removal
- **Enhanced patient comfort:** automatically flakes off as the wound heals or may be removed easily and atraumatically if required as it adheres without using adhesives



**HOW IT WORKS:**  
pHEMA (contact lens material) based dressing, scientifically engineered to provide an ideal wound healing environment

Its granules absorb moisture to transform into a transparent, skin-like barrier that seals and protects the wound

Prevents entry of exogenous bacteria

Permits oxygen transportation

Facilitates exudate management via vapor transportation