

Sawyer Cimaroli, MD; Avi Hatami, MD; Brian Gillette, PhD; Scott Gorenstein, MD | NYU Langone Long Island Hospital, Department of General Surgery
SAWC Fall 2022 Meeting, Las Vegas, NV | October 13-16

INTRODUCTION:

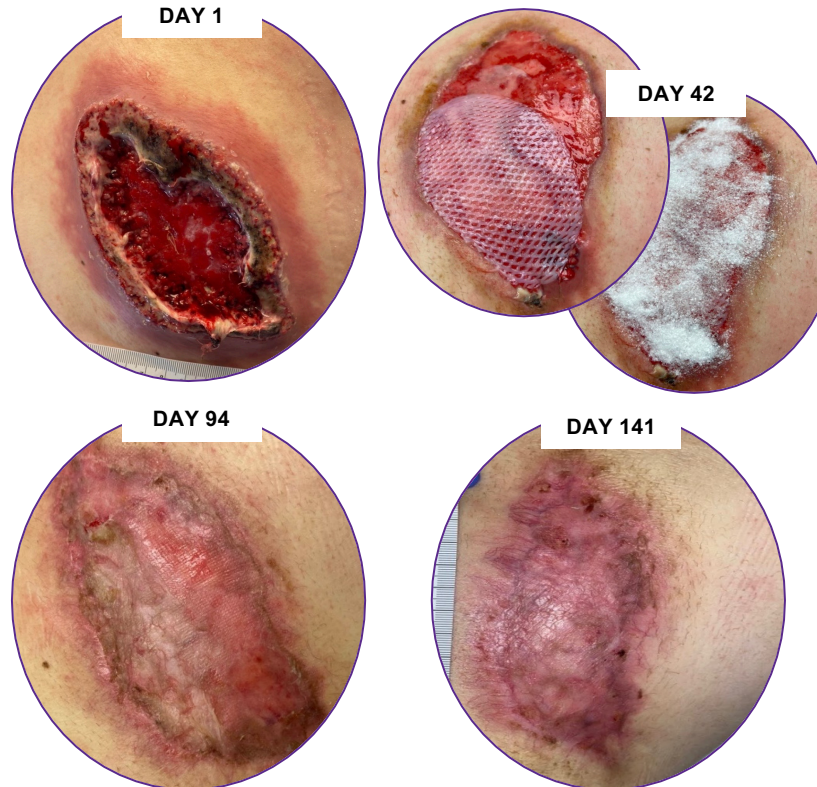
- Pyoderma Gangrenosum (PG) is neutrophilic dermatosis, often associated with malignancy and inflammatory/autoimmune conditions
- PG is characterized by pathergy-exaggerated response to or worsening of even a minor skin injury
- Treatment varies from systemic topical steroids to systemic immunosuppression
- Here we describe a case of PG treated with Prednisone, a bioengineered skin substitute (Apligraf) and transforming powder dressing (TPD*)

CASE DISCUSSION:

- 63-year-old male with a past medical history significant for Hepatitis B who presented to clinic for evaluation of a non-healing wound of the back which had been increasing in size following an excision of an epidermal inclusion cyst two months prior
- A biopsy was suggestive of PG

TREATMENT:

- Patient was started on a prednisone taper and local wound care with weekly application of bioengineered skin substitute and a transforming powder dressing



CONCLUSION:

- Wound has decreased in size from 88.3 cm² to 25.2 cm² (72%) and treatment is ongoing
- Since PG is diagnosed by exclusion of other possible ailments, the diagnosis of PG is often delayed or missed altogether
- Prompt recognition and initiation of treatment is essential

This case supports the use of bioengineered skin substitute and transforming powder dressing as adjuncts to systemic steroids in the treatment of Pyoderma Gangrenosum.

REFERENCES &

ACKNOWLEDGEMENTS:

- Gangrenosum. [Updated 2022 Jul 5]. In: StatPearls [Internet]. Treasure Island (FL): StatPearls Publishing; 2022 Jan-.
- Duchini G, Itin P, Arnold A. A case of refractory pyoderma gangrenosum treated with a combination of Apligraf and systemic immunosuppressive agents. *Adv Skin Wound Care.* 2011;24(5):217-220.
- Acknowledgements:** This case study was conducted independently by the authors and no compensation was paid to the authors. This poster was presented in collaboration with ULURU Inc. For application instructions and risks of this device refer to Altrazeal Instructions for Use.