

# TRANSFORMING POWDER DRESSING (TPD) FOR DIABETIC ULCER CARE PATIENT CASE SERIES

H. David Gottlieb, DPM DABPM, FAPWCA; Podiatrist; Kiana Trent DPM, FABPM, FASPS | VA Maryland HealthCare System

Symposium on Advanced Wound Care (SAWC) Spring 2024 Meeting | Orlando, FL

## INTRODUCTION

Currently, diabetic foot ulcers (DFUs) have no standardized protocols for wound treatment except for offloading and there is a paucity of randomized clinical trials to guide best practices. The study, “Randomized Clinical Trial to Compare Transforming Powder Dressing (TPD\*) and Standard of Care (SOC) Dressing Therapies to Heal Diabetic Foot Ulcers” is currently ongoing, funded by the Naval Medical Research Command (NMRC) – Naval Advanced Medical Development (NAMD) via the Medical Technology Enterprise Consortium (MTEC).

TPD is a commercially available wound dressing with an extended wear time of up to 30-days. In the presence of moisture, the powder coagulates to create a moist, oxygen permeable barrier that protects the wound from contamination while allowing the flow of excess exudate through vapor transpiration. We present four patients who have completed the trial at one site.

## METHODOLOGY

Prospective, multi-center, open-label, interventional study comparing the effectiveness of TPD treatment to SOC dressings in subjects with Wagner Grade 1 and 2 DFUs. Subjects were randomized 1:1 to either SOC or TPD. Treatment involved up to 12 weekly visits with reapplications of TPD as needed. Control group was treated weekly (up to 12 weeks) with standard of care treatment, per the podiatrist’s choice. Both groups received vascular testing to evaluate adequacy of blood flow and were prescribed appropriate off-loading.

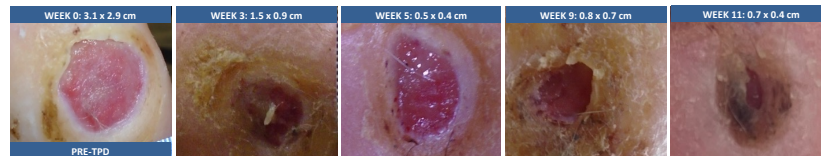
## PATIENT CASE SERIES

### PATIENT 1: TREATED WITH TPD

**History:** 52 y/o male with diabetes type 2 (Hgb A1C=7), hypertension, neuropathy, with 3 DFUs on the right foot. Study wound: Wagner Grade 1  
**Wound Duration:** 1 year | **Wound Dimension:** 3.1 cm (L) x 2.9 cm (W) post debridement

#### Initial Treatment:

- SOC dressings every 4-5 days prior to enrolling in study
- “Slightly smaller” wound after 1 year of SOC treatment

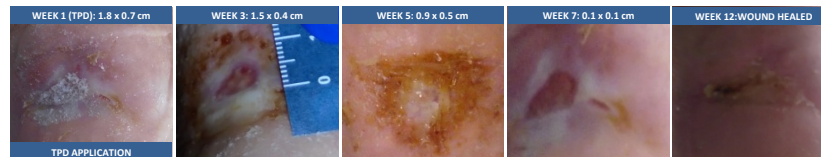


### PATIENT 2: TREATED WITH TPD

**History:** 74 y/o male with diabetes type 2 (Hgb A1C= 6.9), hypertension, COPD, neuropathy, ABI =0.89. He had multiple foot wounds, including a left Wagner Grade 1 DFU

**Wound Duration:** 5 years | **Wound Dimension:** 1.5 (L) x 0.5 (W) cm

**Initial Treatment:** Daily SOC dressings, plus application of skin substitutes resulting in smaller wound, but did not heal

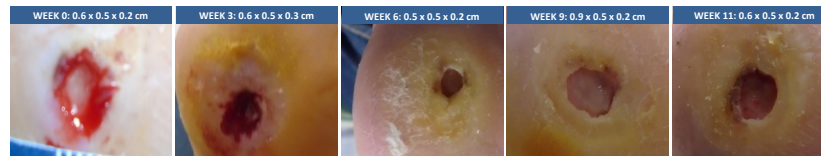


### PATIENT 3: TREATED WITH SOC

**History:** 79 y/o male with diabetes type 2 (Hgb A1C=6.8), hypertension, peripheral vascular disease, COPD with 1 Wagner Grade 1 DFU on left forefoot

**Wound Duration:** 11 years | **Wound Dimension:** 0.6 x 0.5 x 0.2 cm

**Initial Treatment:** Antimicrobial dressing (2-3x / week)

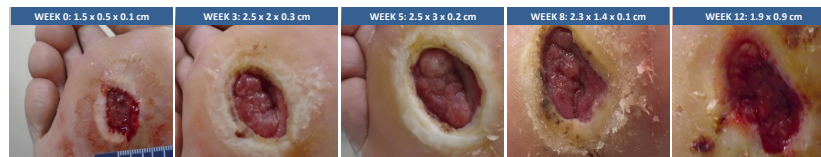


### PATIENT 4: TREATED WITH SOC

**History:** 56 y/o male with diabetes type 2 (Hgb A1C=7.9), hypertension, neuropathy, with 1 plantar Wagner Grade 1 DFU

**Wound Duration:** 3 years | **Wound Dimension:** 1.5 x 0.5 x 0.1 cm

**Initial Treatment:** Daily SOC dressings, resulting in smaller wound, but did not heal



## RESULTS

Four male diabetic subjects with Wagner Grade 1 DFUs were enrolled at one site. Two subjects were randomized to each group. Subjects (52-79 years (mean = 62 years)), had DFUs for 1 year to 11 years duration (mean = 5 years). Mean wound surface area size was 1.7cm<sup>2</sup> (range 0.6cm<sup>2</sup> to 5cm<sup>2</sup>). Both DFUs in the TPD treatment group healed with fewer dressing changes while the DFUs in the control group did not.

Subjects	Wound Duration	Time to Heal	Dressing Changes (Pre-Study*)	Dressing Changes (During-Study)	Debridements	WSA Reduction	Wound Related Complications
TPD 1	1 year	12 weeks	54	40	10**	99%	None
TPD 2	5 years	10 weeks	70	15	2	100%	None
SOC 1	11 years	Did not heal	59	59	12	0	None
SOC 2	3 years	Did not heal	70	70	9	0***	Infection

## DISCUSSION

Initial results of our study indicated that implementation of TPD treatment in subjects with Wagner Grade 1 DFUs refractory to SOC result in improvement in overall wound healing and patient reported satisfaction. Analysis of additional subjects enrolled in this study will be performed upon study close-out.

TPD, in this limited evaluation, has proven to be an effective treatment for Wagner Grade 1 DFUs (along with appropriate offloading) and reduced the frequency for required debridements and dressing changes. TPD is self stable and easily applied in the outpatient environment by the clinician. It has been well tolerated by the active study population. The author has no financial interest in any product used during the course of treatment.

**Funding Sponsor:** Naval Medical Research Command (NMRC)-Naval Advanced Medical Development (NAMD) through Medical Technology Enterprise Consortium (MTEC).

**Acknowledgements:** This material is the result of work supported with resources and the use of facilities at the VA Maryland Health Care System, Baltimore, Maryland. The author has no financial interest in any product used during the course of treatment. The contents do not represent the views of the U.S. Department of Veterans Affairs or the United States Government. For application instructions and risks of this device please refer to Altrazeal Instructions for Use. | EDU-0146